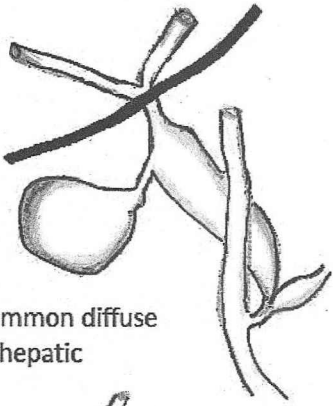
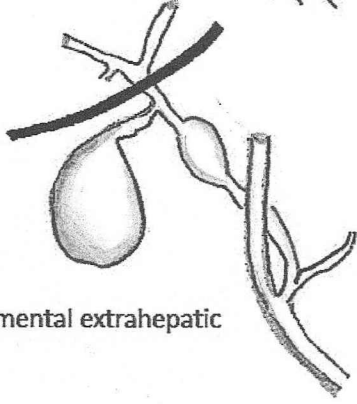


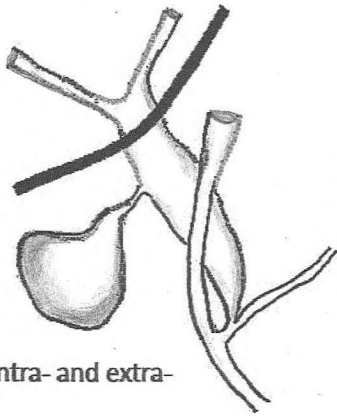
IA Common diffuse extrahepatic



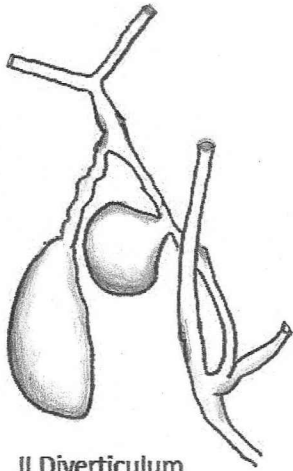
I-B Segmental extrahepatic



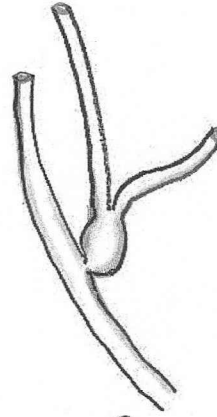
I-C Diffuse intra- and extra-hepatic



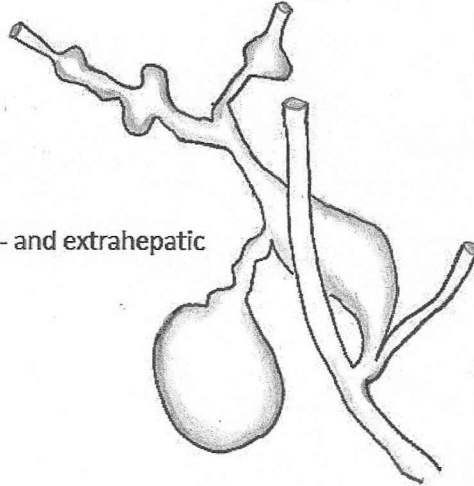
II Diverticulum



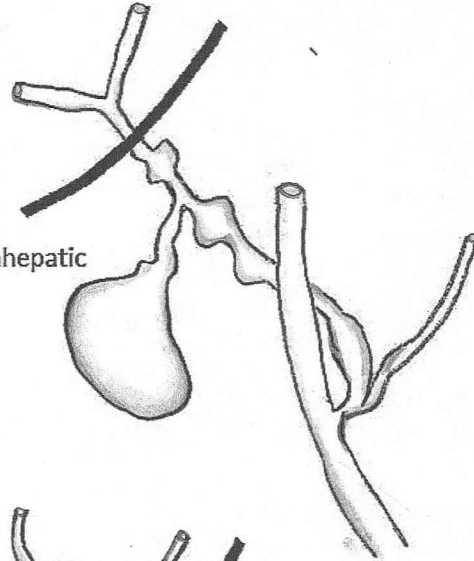
III Choledochocoele



IV-A Intra- and extrahepatic



IV-B Multiple extrahepatic



V Intrahepatic

